

ISSN 2224-526X

ҚАЗАҚСТАН РЕСПУБЛИКАСЫ  
ҰЛТТЫҚ ҒЫЛЫМ АКАДЕМИЯСЫНЫҢ  
Қазақ ұлттық аграрлық университеті

# Х А Б А Р Л А Р Ы

## ИЗВЕСТИЯ

НАЦИОНАЛЬНОЙ АКАДЕМИИ НАУК  
РЕСПУБЛИКИ КАЗАХСТАН  
Қазақстан Республикасының  
Ұлттық аграрлық университеті

## IZVESTIÂ

NATIONAL'NOJ AKADEMII NAUK  
RESPUBLIKI KAZAHSTAN  
Kazakh national  
agrarian university

### SERIÂ AGRARNYH NAUK

## 6 (54)

NOVEMBER – DECEMBER 2019

PUBLISHED SINCE JANUARY 2011

PUBLISHED 6 TIMES A YEAR

ALMATY, NAS RK

Б а с р е д а к т о р

**Есполов Т.И.,**

э.ғ.д, профессор,

ҚР ҰҒА академигі және вице-президенті

Р е д а к ц и я а л қ а с ы:

**Байзақов С.Б.**, э.ғ.д, проф., ҚР ҰҒА академигі (бас редактордың орынбасары); **Тиреуов К.М.**, э.ғ.д, проф., ҚР ҰҒА академигі (бас редактордың орынбасары); **Елешев Р.Е.**, т.ғ.д., проф., ҚР ҰҒА академигі; **Рау А.Г.**, т.ғ.д., проф., ҚР ҰҒА академигі; **Иванов Н.П.**, в.ғ.д, проф., ҚР ҰҒА академигі; **Кешуов С.А.**, т.ғ.д., проф., ҚР ҰҒА академигі; **Мелдебеков А.**, а.ш.ғ.д., проф., ҚР ҰҒА академигі; **Чоманов У.Ч.**, т.ғ.д., проф., ҚР ҰҒА академигі; **Елюбаев С.З.**, а.ш.ғ.д., проф., ҚР ҰҒА академигі; **Садықұлов Т.**, а.ш.ғ.д., проф., академигі; **Баймұқанов Д.А.**, а.ш.ғ.д., проф., ҚР ҰҒА корр-мүшесі; **Сансызбай А.Р.**, а.ш.ғ.д., проф., ҚР ҰҒА корр-мүшесі; **Умбетаев И.**, а.ш.ғ.д., проф., ҚР ҰҒА академигі; **Оспанов С.Р.**, а.ш.ғ.д., проф., ҚР ҰҒА құрметті мүшесі; **Олейченко С.И.**, а.ш.ғ.д., проф.; **Кененбаев С.Б.**, а.ш.ғ.д., проф., ҚР ҰҒА корр-мүшесі; **Омбаев А.М.**, а.ш.ғ.д., проф. ҚР ҰҒА корр-мүшесі; **Молдашев А.Б.**, э.ғ.д., проф., ҚР ҰҒА құрметті мүшесі; **Сагитов А.О.**, б.ғ.д., ҚР ҰҒА академигі; **Сапаров А.С.**, а.ш.ғ.д., проф., ҚР АШҒА академигі; **Балгабаев Н.Н.**, а.ш.ғ.д., проф.; **Умирзаков С.И.**, т.ғ.д, проф.; **Султанов А.А.**, в.ғ.д., проф., ҚР АШҒА академигі; **Алимкулов Ж.С.**, т.ғ.д., проф., ҚР АШҒА академигі; **Сарсембаева Н.Б.**, в.ғ.д., проф.

Р е д а к ц и я к е н е с і:

**Fasler-Kan Elizaveta**, Dr., University of Basel Switzerland; **Koolmees Petrus Adrianus**, Prof. Dr., Utrecht University, The Netherlands; **Babadoost-Kondri Mohammad**, Prof., University of Illinois, USA; **Yus Aniza Binti Yusof**, Dr., University Putra, Malaysia; **Hesseln Hayley Fawn**, As. Prof., University of Saskatchewan, Canada; **Alex Morgounov**, Pr., International Maize and Wheat Improvement Center Turkey; **Андреш С.**, Молдова Республикасы ҰҒА академигі; **Гаврилюк Н.Н.**, Украина ҰҒА академигі; **Герасимович Л.С.**, Беларусь Республикасының ҰҒА академигі; **Мамедов Г.**, Азербайжан Республикасының ҰҒА академигі; **Шейко И.П.**, Беларусь Республикасының ҰҒА академигі; **Жалнин Э.В.**, т.ғ.д., проф., Ресей; **Боинчан Б.**, а.ш.ғ.д, проф., Молдова Республикасы; **Юлдашбаев Ю.А.**, а.ш.ғ.д, проф., РФА корр-мүшесі, Ресей.

Главный редактор

**Есполов Т.И.,**

доктор эконом. наук, проф.,  
вице-президент и академик НАН РК

Редакционная коллегия:

**Байзаков С.Б.**, доктор эконом. наук, проф., академик НАН РК (заместитель главного редактора); **Тиреуов К.М.**, доктор эконом. наук, проф., академик НАН РК (заместитель главного редактора); **Елешев Р.Е.**, доктор техн. наук, проф., академик НАН РК; **Рау А.Г.**, доктор техн. наук, проф., академик НАН РК; **Иванов Н.П.**, доктор ветеринар. наук, проф., академик НАН РК; **Кешуов С.А.**, доктор техн. наук, проф., академик НАН РК; **Мелдебеков А.**, доктор сельхоз. наук, проф., академик НАН РК; **Чоманов У.Ч.**, доктор техн. наук, проф., академик НАН РК; **Елюбаев С.З.**, доктор сельхоз. наук, проф., академик НАН РК; **Садыкулов Т.**, доктор сельхоз. наук, проф., академик НАН РК; **Баймуканов Д.А.**, доктор сельхоз. наук, проф., член-корр. НАН РК; **Сансызбай А.Р.**, доктор сельхоз. наук, проф., член-корр. НАН РК; **Умбетаев И.**, доктор сельхоз. наук, проф., академик НАН РК; **Оспанов С.Р.**, доктор сельхоз. наук, проф., Почетный член НАН РК; **Олейченко С.И.**, доктор сельхоз. наук, проф.; **Кененбаев С.Б.**, доктор сельхоз. наук, проф., член-корр. НАН РК; **Омбаев А.М.**, доктор сельхоз. наук, проф. член-корр. НАН РК.; **Молдашев А.Б.**, доктор эконом. наук, проф., Почетный член НАН РК; **Сагитов А.О.**, доктор биол. наук, академик НАН РК; **Сапаров А.С.**, доктор сельхоз. наук, проф., академик АСХН РК; **Балгабаев Н.Н.**, доктор сельхоз. наук, проф.; **Умирзаков С.И.**, доктор техн. наук, проф.; **Султанов А.А.**, доктор ветеринар. наук, проф., академик АСХН РК; **Алимкулов Ж.С.**, доктор техн. наук, проф., академик АСХН РК; **Сарсембаева Н.Б.**, доктор ветеринар. наук, проф.

Редакционный совет:

**Fasler-Kan Elizaveta**, Dr., University of asel Switzeland; **Koolmees Petrus Adrianus**, Prof. Dr., Utrecht University, The Netherlands; **Babadoost-Kondri Mohammad**, Prof., University of Illinois, USA; **Yus Aniza Binti Yusof**, Dr., University Putra, Malaysia; **Hesseln Hayley Fawn**, As.Prof., University of Saskatchewan, Canada; **Alex Morgounov**, Pr., International Maize and Wheat Improvement Center Turkey; **Андреш С.**, академик НАН Республики Молдова; **Гаврилюк Н.Н.**, академик НАН Украины; **Герасимович Л.С.**, академик НАН Республики Беларусь; **Мамедов Г.**, академик НАН Республики Азербайджан; **Шейко И.П.**, академик НАН Республики Беларусь; **Жалнин Э.В.**, доктор техн. наук, проф., Россия; **Боинчан Б.**, доктор сельхоз. наук, проф., Республика Молдова; **Юлдашбаев Ю.А.**, доктор сельхоз. наук, проф., член-корр. РАН, Россия.

**Известия Национальной академии наук Республики Казахстан. Серия аграрных наук.**

**ISSN 2224-526X**

Собственник: ООО «Национальная академия наук Республики Казахстан» (г. Алматы)

Свидетельство о постановке на учет периодического печатного издания в Комитете информации и архивов Министерства культуры и информации Республики Казахстан № 10895-Ж, выданное 30.04.2010 г.

Периодичность 6 раз в год

Тираж: 300 экземпляров

Адрес редакции: 050010, г. Алматы, ул. Шевченко, 28, ком. 219-220, тел. 272-13-19, 272-13-18

<http://agricultural.kz/index.php/en/>

---

© Национальная академия наук Республики Казахстан, 2019

Адрес типографии: ИП «Аруна», г. Алматы, ул. Муратбаева, 75

Chief Editor

**Espolov T.I.,**

Dr. economy. Sciences, prof.,  
Vice President and academician of the NAS RK

Editorial Board:

**Baizakov S.B.**, Dr. of economy sciences, prof., academician of NAS RK (deputy editor); **Tireuov K.M.**, Doctor of Economy Sciences., prof., academician of NAS RK (deputy editor); **Eleshev R.E.**, Dr. Of agricultural sciences, prof., academician of NAS RK; **Rau A.G.**, Dr. sciences, prof., academician of NAS RK; **Ivanov N.P.**, Dr. of veterinary sciences, prof., academician of NAS RK; **Keshuov S.A.**, Dr. sciences, prof., academician of NAS RK; **Meldebekov A.**, doctor of agricultural sciences, prof., academician of NAS RK; **Chomanov U.Ch.**, Dr. sciences, prof., academician of NAS RK; **Yelyubayev S.Z.**, Dr. of agricultural sciences, prof., academician of NAS RK; **Sadykulov T.**, Dr. Farm. Sciences, prof., academician of NAS RK; **Baimukanov D.A.**, doctor of agricultural sciences, prof., corresponding member NAS RK; **Sansyzbai A.R.**, doctor of agricultural sciences, prof., corresponding member NAS RK; **Umbetaev I.**, Dr. Farm. Sciences, prof., academician of NAS RK; **Ospanov S.R.**, Dr. agricultural sciences, prof., Honorary Member of NAS RK; **Oleychenko S.N.**, Dr. Of agricultural sciences, prof.; **Kenenbayev S.B.**, Dr. Agricultural sciences, prof., corresponding member NAS RK; **Ombayev A.M.**, Dr. Agricultural sciences, Prof. corresponding member NAS RK; **Moldashev A.B.**, Doctor of Economy sciences, prof., Honorary Member of NAS RK; **Sagitov A.O.**, Dr. biol. sciences, academician of NAS RK; **Saparov A.S.**, Doctor of agricultural sciences, prof., academician of NAS RK; **Balgabaev N.N.**, the doctor agricultural sciences, Prof.; **Umirzakov S.I.**, Dr. Sci. Sciences, Prof.; **Sultanov A.A.**, Dr. of veterinary sciences, prof., academician of the Academy of Agricultural Sciences of Kazakhstan; **Alimkulov J.C.**, Dr. of technical sciences, prof., academician of the Academy of Agricultural sciences of Kazakhstan; **Sarsembayeva N.B.**, Dr. veterinary sciences, prof.

Editorial Board:

**Fasler-Kan Elizaveta**, Dr., University of Basel Switzerland; **Koolmees Petrus Adrianus**, Prof. Dr., Utrecht University, The Netherlands; **Babadoost-Kondri Mohammad**, Prof., University of Illinois, USA; **Yus Aniza Binti Yusof**, Dr., University Putra, Malaysia; **Hesseln Hayley Fawn**, As. Prof., University of Saskatchewan, Canada; **Alex Morgounov**, candidate of agricultural sciences, International Maize and Wheat Improvement Center Turkey; **Andresh S.**, academician of NAS of Moldova; **Gavriluk N.N.**, academician of NAS of Ukraine; **Gerasimovich L.S.**, academician of NAS of Belorussia; **Mamadov G.**, academician of NAS of Azerbaijan; **Sheiko I.P.**, academician of NAS of Belorussia; **Zhalnin E.V.**, Dr. of technical sciences, professor, Russia, **Boinchan B.**, doctor of agricultural sciences, prof., Moldova; **Yuldashbayev Y.A.**, doctor of agricultural sciences, prof., corresponding member of RAS, Russia.

**News of the National Academy of Sciences of the Republic of Kazakhstan. Series of Agrarian Sciences.**  
**ISSN 2224-526X**

Owner: RPA "National Academy of Sciences of the Republic of Kazakhstan" (Almaty)

The certificate of registration of a periodic printed publication in the Committee of Information and Archives of the Ministry of Culture and Information of the Republic of Kazakhstan N 10895-Ж, issued 30.04.2010

Periodicity: 6 times a year

Circulation: 300 copies

Editorial address: 28, Shevchenko str., of.219-220, Almaty, 050010, tel. 272-13-19, 272-13-18,

<http://nauka-nanrk.kz/agricultural.kz>

---

© National Academy of Sciences of the Republic of Kazakhstan, 2019

Address of printing house: ST "Aruna", 75, Muratbayev str, Almaty

## NEWS

OF THE NATIONAL ACADEMY OF SCIENCES OF THE REPUBLIC OF KAZAKHSTAN  
SERIES OF AGRICULTURAL SCIENCES

ISSN 2224-526X

Volume 6, Number 54 (2019), 5 – 12

<https://doi.org/10.32014/2019.2224-526X.70>

UDK 616-036.22

**A. Balgimbayeva, G. Shabdarbaeva, L. Zhanteliyeva, A. Ibazhanova, D. Khussainov**

Kazakh National Agrarian University, Almaty, Kazakhstan.

E-mail: shgs52@mail.ru, laura.zhanteli.@kaznau.kz, sema.serikova@mail.ru, doctor-vet@mail.ru

**DIAGNOSTICS AND TREATMENT  
OF DIOCTOPHYMOSIS IN DOGS**

**Abstract.** This article includes materials on the rare disease in domestic and wild carnivores, dioctophimosis, caused by a helminth from the group of aphasmodia nematodes, *Dioctophyme renale*, which is parasitic in the kidneys, recently registered in veterinary clinics in Almaty. The disease has important social significance - a person is susceptible to it, the infection of which occurs when raw fish is eaten. In Almaty, according to the statistics of veterinary clinics in recent years (2018-2019), 17 cases of dioctophimosis in dogs have been registered, that is up to 0.3% of the number of dogs examined for helminthiasis. The appearance of this disease, which is relatively new for our region, can have a significant impact on the epizootiological and epidemiological situation. The results of in vivo laboratory diagnosis of dioctophimosis in dogs by ovoscopic methods are presented, with the provision of microphotos of the parasite eggs; methods of instrumental diagnostics - ultrasound examination (ultrasound) of the kidneys with the provision of photos proving the presence of a parasite in the renal pelvis. Since the only treatment for dioctophimosis is surgery and extraction of dioctophyma from the affected organ (kidney), our own original materials are presented for a step by step surgical intervention to extract helminth from the kidneys of dogs and treat animals. The condition of the operated animals is satisfactory, the prognosis for surgery is favorable.

**Key words:** dogs, carnivores, helminths, helminthiasis, monitoring, nematodes, epizootiological and epidemiological situation, hematuria, dioctophimosis, ultrasound, OIE, WHO, invasive material, urine, feces, kidneys, surgical treatment.

**Relevance of research.** Dioctophimosis (code according to ICD-10 - B83.9) is a helminthiasis disease of silver-black foxes, dogs, jackals, marten and other carnivores, as well as humans when eating raw fish. The disease is characterized by damage to the kidneys, renal pelvis, ureters, bladder, abdominal cavity, sometimes the liver, blood vessels and heart; manifested by intoxication of the body, uremic phenomena, bloody urine. The literature describes cases of human infection with dioctophyma and rarely cattle. The disease relates to the group of helminthiasis caused by aphasmodia nematodes [1, 2].

The systematic position of the dioctophimosis pathogen [1]:

Class -

Subclass -

Order -

Suborder -

Superfamily -

Family -

Genus -

Specie -

The *Dioctophyme renale* pathogen, is a nematode referring to the Dioctophymidae family, the only specie of the Dioctophyme. *D. renale* genus, represents sexual dimorphism and is considered the largest nematode, which infects the domestic animals, males can reach a length of 40 cm, and females can reach up to 100 cm [3]. The female has the rounded tail end, its vulva opens at the level of the initial part of the esophagus. The male has the tail end, which ends with a bell-shaped bursa, from which a spicule protrudes. The papillary tubercles in the form of two circles are around the mouth of the helminth [2].

Reproduction occurs by discharging eggs of 0.077 - 0.083x0.046 - 0.047 mm, brown, with lids at the poles. The egg shell consists of three layers: the outer, inner and vitelline membrane. The surface of the egg is dotted with small impressions like pockets. Eggs are secreted into the environment with the urine of a sick animal [2].

Dioctophyma are biohelminths. The pathogen development takes place with the participation of two hosts: definitive and intermediate hosts.

Definitive hosts: The main definitive hosts are ermines and canids. However, this nematode has been reported in pigs, cats, horses, cattle and other mammals such as wild cat, cheetah, coati, foid densification, mongoose rat [4]; and about 24 cases have been reported in humans [5], therefore, it is considered a zoonotic disease.

Intermediate hosts: *Branchiobdella* or *Lumbriculus* oligochaetes.

Additional and reservoir hosts: fish (sabrefish, perch, barbel, mackerel, spike, shovel, pike, catfish, gambusia and some other cyprinids), in the body of which helminth larvae are encapsulated, remaining viable for a long time [2].

Sexually mature females, localized in a sick animal in the renal pelvis, ureters, and bladder, lay eggs, which are excreted with the urine into the external environment. Eggs, which fall into the water, are developed within 25 to 30 days. They form larvae, which reach 0.28 - 0.31 mm in length.

The eggs with developed larvae are swallowed together with detritus by the first intermediate hosts - oligochaetes of the *Branchiobdella* or *Lumbriculus* genus. In the intestine of the oligochaetes, larva emerges from the egg and migrates into the abdominal blood vessel, where it grows and develops. After 45-60 days, depending on the water temperature, the first molt occurs and the larva turns into the second stage, reaching 0.885-1.181 mm in length. After 3.5 - 4 months the larva molts for a second time and turns into a third-stage larva, reaching 6.905 - 8.018 mm in length. At this stage of larval development, young males and females are formed.

Oligochaetes infected by invasive larvae are eaten by fish, the second intermediate hosts (sicklefish, perch, barbel, shemaya, ship, shovelnose sturgeon, pike, catfish, gambusia and some other cyprinids) [2].

The further development of the third stage larva occurs only in the organism of the definitive host, where it can enter together with the oligochaetes or with infected fish. Larvae of dioctofimide, once entered in the intestines of the final host (carnivores or humans), penetrate its wall, enter the body cavity and migrate through the body, reaching the renal pelvis. At this time, the larvae molt twice. The life cycle of dioctofimide is completed in 8.5 - 9 months.

The lifespan of a nematode in the organism of a definitive host is up to 3-5 years [2].

Epizootological data. Locally, dioctophimosis of carnivores is found in areas of Transcaucasia, Central Asia, Kazakhstan, the Far East, Karelia and Siberia in large river basins. Dioctophimosis is registered in far abroad countries: Italy, Austria, Germany, Holland, France, England, Japan, North and South America [2]. For example, infection of dogs in some areas of North America reaches up to 37%, in Kazakhstan it ranges from 1 to 9% [6]. This parasite has a worldwide distribution, however, most reports have been received from South-East Asia [7.8].

Epidemiology. Human dioctophimosis is registered in many countries of the world: Argentina, Paraguay, Brazil, the USA, a number of European countries, Iran, South Vietnam, China, Japan. In the CIS countries, it is more often found in Tajikistan, Uzbekistan, Kazakhstan, isolated cases are registered in Leningrad and Arkhangelsk regions. Since annelids (intermediate hosts of *Dioctophyme renale*) live on the wet coasts of water bodies, endemic foci are confined to river valleys and lakes [6].

Symptoms and pathogenesis. Mostly sexually mature helminths are localized in animals in the kidneys and less often in the abdominal cavity. But, before getting there, nematodes migrate from the stomach of a mammal, where they get with fish or oligochaetes. They invade the muscle layer of the stomach wall, causing a hematoma. Then they migrate to the body cavity and are closer to the liver. Penetrate into its parenchyma, and then into the renal pelvis. As a result, its wall is greatly stretched and thinned, the kidney atrophies. Sometimes the nematode enters the urethra. All this leads to significant violations of these organs and painful phenomena of the whole organism. An animal or a human does not have appetite, vomiting, general exhaustion, and an oppressed state appear. A muddy, bloody liquid accumulates inside the renal pelvis, its smell resembles that of urine. The mucous membrane of the renal

pelvis becomes grayish-white or yellowish in color. In places of degenerated areas, the lime salt are deposited in the form of multiple lumps [2,6].

Pathological changes in the human body at the onset of the disease are associated with the migration of larvae into the abdominal cavity and into the liver, which is accompanied by hemorrhages, serous-fibrinous inflammation of the mesentery, venous congestion in the liver, and the formation of granulomas and scars at the sites of damage. During parasitization of adult helminths in the human renal pelvis, the kidney parenchyma is destroyed step by step, and the capsule is preserved only. The right cavity, directly adjacent to the duodenum, from which the parasite larvae migrate, is more often affected [6, 9].

The most characteristic symptoms of the disease are renal colic, pyuria, hematuria, oliguria and anuria. Often there are complaints of pain in the lumbar region, which spread throughout the abdomen.

Complications in humans are renal coma [6.10].

In fish, *Dioctophyme renale* larvae reach 6.9 - 8.2 mm in length and 0.19 - 0.2 mm in width. They are localized in the internal organs: in the intestinal wall, on the peritoneum, mesentery, in the gonads, a connective tissue capsule is formed around them.

Diagnosis. To make a diagnosis during life, urine is examined for the parasite eggs and an ultrasound examination of the kidneys (ultrasound) is performed. Posthumously, disease is diagnosed on the basis of an autopsy of animals and finding a nematode in the kidney, less commonly in other organs [2].

When examining the fish, encapsulated larvae are found in the intestine, mesentery, and gonads [2].

Treatment. The only treatment at this time is surgery and extraction of *Dioctophyme renale* from the affected organ. There is evidence of attempts to treat animals with ivomek, praziquantel, levomizole, etc. [2, 6, 11].

Prevention of the disease is to identify dysfunctional water bodies and prohibit to feed the animals with raw fish. In areas unfavorable due to dioctophimosis, dogs are not allowed to sites of catching and cutting fish. The diet of fur-bearing animals excludes the raw fresh fish caught in reservoirs unsuccessful due to this invasion. They explanatory work is conducted among fisheries workers and among the population on the prevention of dioctophimosis [12,13,14,15,16].

The epidemiological and epidemiological situation with many helminthiases of carnivores, especially in zoonotic helminthiases in Kazakhstan and in neighboring countries, should be improved. In the world, especially in tropical and subtropical countries, the epidemiological and epidemiological situation regarding zoonotic helminthiases is very problematic. For example, according to the classification of the Office International des Epizooties (OIE), some helminthiases, in particular echinococcosis, which is spread among population and productive animals by the carnivorous, are included in the list of the most common diseases and in many countries are included in national programs to eliminate the disease. The annual costs for treating patients and losses in animal husbandry are amounted to USD 3 bln. Kazakhstan is among the regions permanently unfavorable for echinococcosis. World experience shows that establishing the incidence of helminth infections in animals allows us to assess the degree of threat to humans. According to the World Health Organization (WHO), every year a quarter of the population (more than 1.4 billion people) is infected with parasites, the most significant group of which is helminths. Nematodoses are the most common of the helminthiases [17].

Kazakhstan also has a difficult epidemiological and epidemiological situation regarding zoonotic helminthiases. From the State report on the situation in Kazakhstan, it follows that the epidemiological situation with parasitosis in the country poses a threat to public health. About 20,000 cases of parasitosis are recorded annually in Kazakhstan, the intensive incidence rate is on average about 24.2 per 100 thousand people. A number of researchers (Kereyev Ya.M., 2010; Shalmenov M.Sh., 2005; Akshulakov S.K., 2002; Amireyev S.A., 2002; Shabdarbayeva G.S., Abdibekova A.M., Shapiyeva Zh.Zh., 2012; Lider L.A., 2009; Shabdarbayeva G.S. et al., 2016) note a large infection of carnivores and humans with zoonotic helminthiases [18-23].

In Kazakhstan, a number of scientists performed researches related to monitoring of helminthiases of carnivorous zoonotic helminthiases. 11 species of helminths from different systematic groups were registered in the studied carnivorous. From the class of trematodes, only 1 species was noted - *Opistorhis felineus*; from the cestode class 4 species: *Multiceps multiceps*, *Dipilidium caninum*, *Echinococcus granulosus*, *Alveococcus multilocularis*; from the class of nematodes of 6 species: *Dioctophyme renale*, *Toxocara canis*, *Toxascaris leonina*, *Ancylostoma caninum*, *Trichocephalus vulpis*, *Dirofilaria immitis*.

The greatest invasion in carnivores was noted by various nematodes, in particular, the species *Toxascaris leonina* that amounted to 28.9% of the total number of infected animals. A rather high infection was observed in carnivorous with toxocariasis: 22.4%. Significant invasion was also noted by the species from the cestodes *Dipilidium caninum*, which is 13.8%. All the above types of helminths are dangerous in human infection and can cause significant damage to his health. The remaining helminths, including dioctophimosis (*Dioctophyme renale*) are presented in isolated cases - from 0.7% to 5.8%. The average helminth infection in the studied dogs was 79.6% [24]. Based on the monitoring results, recommendations were suggested on the control of zoonotic helminthiases and on methods for detecting larval stages of helminths in fish [25, 26].

In connection with the increase in the number of livestock, the types of their diseases are also increasing today. Since invasive diseases occur in all types of domestic animals, they cause enormous damage to the national economy. Many invasive diseases, in particular parasitic diseases lead to mass death of animals [27].

**Results.** The studies were carried out in Almaty clinics. 17 cases of a rare helminthiasis nematode disease - dioctophimosis in dogs were registered during 2018-2019.

During the anamnesis, the nature of nutrition of the dogs was ascertained whether the animals were fed with raw fish or not. If so, where was the fish come or purchased from?

Clinical examination was carried out using methods of animal thermometry, focusing on the nature of urination: difficult or not; urination frequency; pain during urination; color and texture of urine.

Then, several portions of urine were obtained from dogs, and urine was centrifuged at 1000 rpm within 1 minute. The supernatant was carefully drained, the suspension remaining at the bottom of the centrifuge tube was pipetted by portions on a glass slide and viewed under a microscope at  $10 \times 40$  magnification. Characteristic *Dioctophyme renale* eggs were found (figure 1). The preliminary clinical diagnosis in all cases was confirmed by intravital urine examination.

During ultrasound examination of the kidneys (ultrasound) contours of 1 or 2 helminths were found in the renal pelvis in dogs. The phenomena of kidney atrophy from squeezing of tissues by a parasite and coagulated helminth in the renal pelvis were observed (figures 2–4).

Having established a positive diagnosis and location of helminths, surgical treatment of dioctophimosis was performed. The progress of operation to extract *Dioctophyme renale* from the kidney is shown in figures 5–16.

At first, the type of anesthesia for the animal was determined. The need and dosage of anesthesia were calculated and given according to the weight of the animal. Next, the access points to the kidney were determined, the incision site was planned, the incision site was treated with aseptic antimicrobial agents, and the abdominal wall was incised. Then, reaching the kidney, suction of fluid collected around the kidney as a result of the inflammatory process was performed.

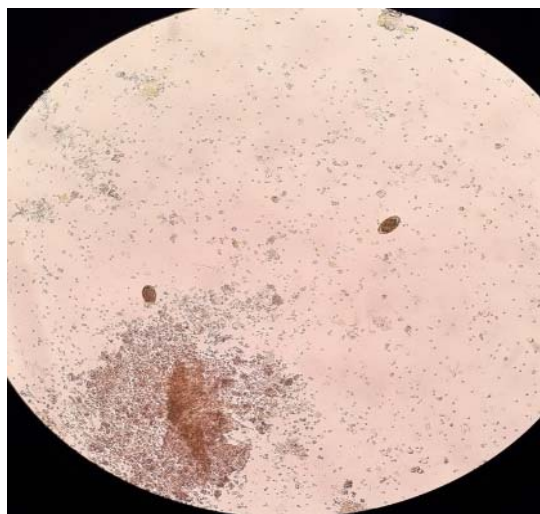


Figure 1 – *Dioctophyme renale* eggs at 10x40

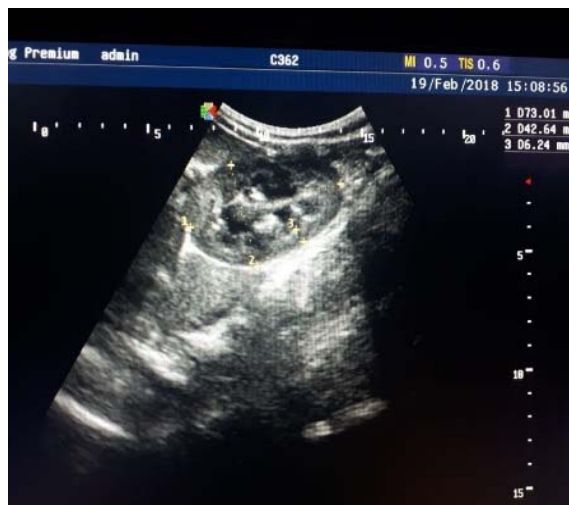

Figure 2 – Dog's kidney ultrasound Results



magnification

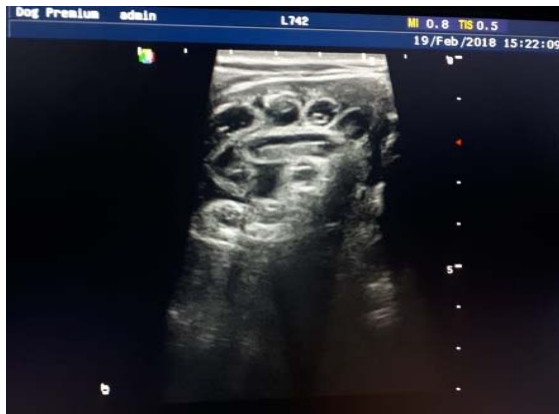

Figure 3 – Diocotphyne renale in the dog's kidney pelvis

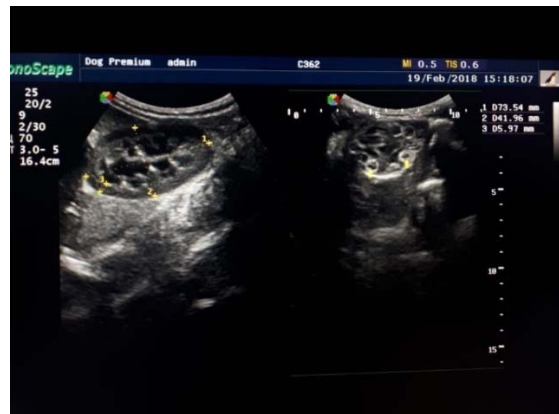

Figure 4 – Dog's kidneys ultrasound examination results

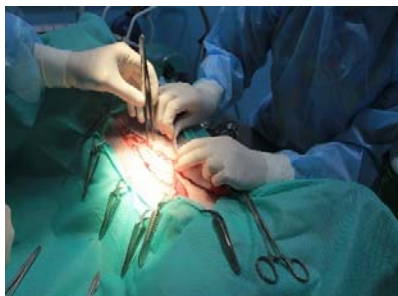

Figure 5 –  
Incision of the abdominal wall

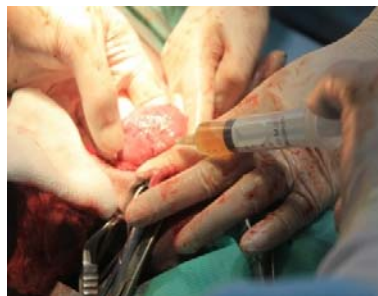

Figure 6 – Suction of fluid  
from the tissues around the kidney

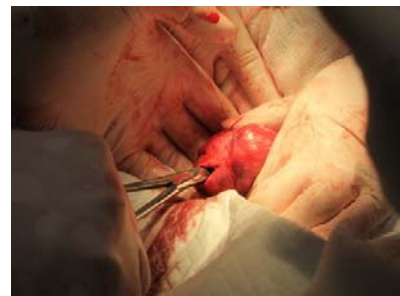

Figure 7 –  
Incision of the kidney wall

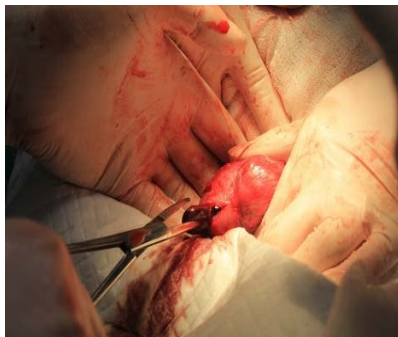

Figure 8 – Capturing helminth  
with forceps

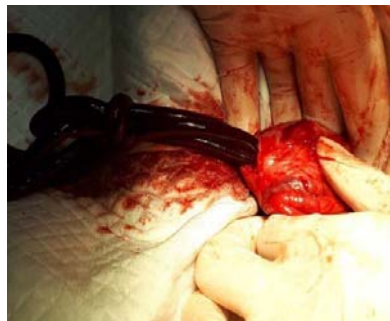

Figure 9 – Removing helminth  
from the kidney

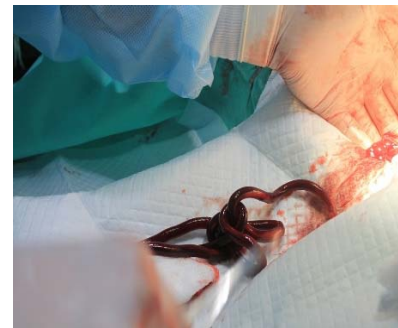

Figure 10 – Helminth extracted  
from the dog's kidney

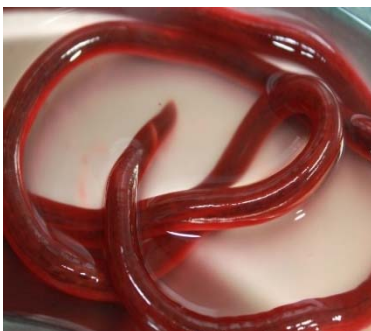

Figure 11 – *Diocotphyne renale*  
from the dog's kidney



Figure 12 – Female and  
male of *Diocotphyne renale*



Figure 13 – Measurement  
of *Diocotphyne renale*

from the dog's kidney

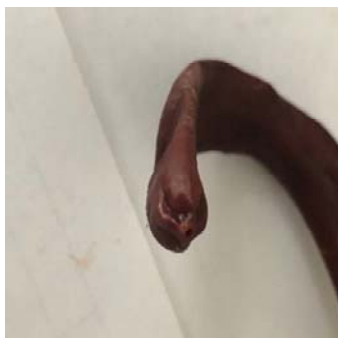

Figure 14 – Head end of *Dioctophyme renale*

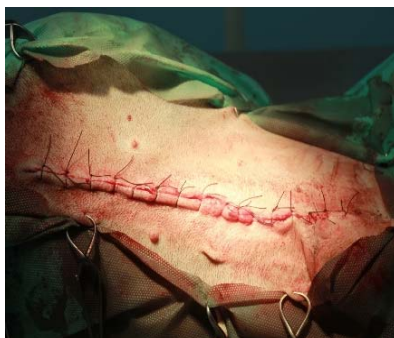

Figure 15 – Suture on the wall of the abdominal cavity after surgery

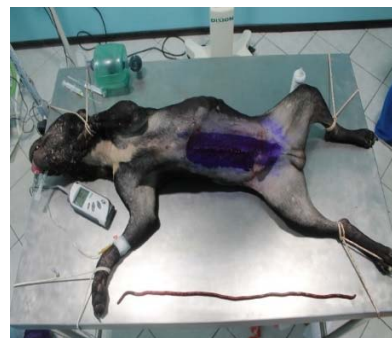

Figure 16 – Postoperative anesthesia in a dog

A small incision was made in the kidney wall, the forceps were carefully inserted into the incision, the helminth was fixed, and removed carefully through the incision using the twisting method (figures 5–9).

The extracted helminths were identified by genus and species, measured, museum preparations were prepared from them, which replenished the parasitological museum of the department.

The condition of the patients after the surgery was satisfactory in all cases, there was no temperature reaction, the food was taken with pleasure, the wound healed by primary intention. Urination is not difficult, the kidneys regained their function.

**Conclusion.** Taking into account the geographical location of Almaty, the lack of large rivers around the metropolis with the above species composition of fish, it becomes clear why there is a very small infection of carnivorous with dioctophimosis. Cases of infection of the dog with dioctophimosis in our clinical practice are apparently imported cases. But infection of carnivores and humans from invasive fish imported from regions unsuccessful for this disease is not excluded.

**А. И. Балгимбаева, Г. С. Шабдарбаева,  
Л. О. Жантелиева, А. С. Ибажанова, Д. М. Хусайнов**

Қазақ ұлттық аграрлық университеті, Алматы, Қазақстан

#### ИТТЕРДІҢ ДИОКТОФИМОЗЫН БАЛАУ ЖӘНЕ ЕМДЕУ

**Аннотация.** Мақалада соңғы уақытта Алматы қаласының ветеринариялық клиникаларында тіркелген, үй және жабайы етқоректі жануарлардың сирек кездесетін ауруы – диоктофимоз, бүйректерде паразиттелетін афазмидиялық нематод тобының гельминті тудыратын *Dioctophyme renale* бойынша материалдар ұсынылған. Аурудың маңызды әлеуметтік мәні бар - адам оған сезімтал, инфекция шикі балық жеген кезде пайда болады. Алматыда соңғы жылдардағы (2018-2019) ветеринарлық клиникалардың статистикасына сәйкес иттерде диоктофимоздың 17 жағдайы тіркелді, бұл гельминтозға тексерілгендердің 0,3% құрайды. Біздің аймақ үшін салыстырмалы түрде жаңа пайда болған бұл аурудың пайда болуы эпизоотологиялық және эпидемиологиялық жағдайға айтарлықтай әсер етуі мүмкін. Иттердегі диоктофимозды тірі кезіндегі зертханалық диагностикасының нәтижелері, паразит жұмыртқаларының микрофотографиясын ұсына отырып, овоскопиялық әдістермен; аспаптық диагностика әдістерімен – бүйректі ультрадыбыстық зерттеу (УДЗ), бүйректің лоханкасында паразиттің болуын дәлелдейтін фотосуреттерді қолдана отырып ұсынылған. Диоктофимозды емдеудің жалғыз әдісі хирургиялық араласу және зақымданған мүшелерден (бүйректен) диоктофимдерді алу болып табылатындықтан, иттерді бүйректен гельминтті алу және жануарларды емдеу мақсатында кезең-кезеңмен оперативтік араласу бойынша өзіндік бірегей материалдар келтірілген. Операциядан өткен жануарлардың жағдайы қанағаттанарлық, операциядан өткен кездегі болжам қолайлы.

**Түйін сөздер:** иттер, ет қоректілер, гельминттер, гельминтоздар, мониторинг, нематодтар, эпизоотологиялық-эпидемиологиялық жағдай, гематурия, диоктофимоз, УДЗ, ХЭБ, ДДҰ, инвазирленген материал, несеп, нәжіс, бүйрек, операциялық емдеу.

А. И. Балгимбаева, Г. С. Шабдарбаева,  
Л. О. Жантелиева, А. С. Ибажанова, Д. М. Хусайнов

Казахский национальный аграрный университет, Алматы, Казахстан

## ДИАГНОСТИКА И ЛЕЧЕНИЕ ДИОКТОФИМОЗА СОБАК

**Аннотация.** В статье представлены материалы по зарегистрированным в последнее время в ветеринарных клиниках г. Алматы редком заболевании домашних и диких плотоядных – диоктофимозе, вызываемом гельминтом из группы афазмидиевых нематод - *Diocotophyme renale*, паразитирующего в почках. Заболевание имеет важное социальное значение – к нему восприимчив человек, заражение которого происходит при употреблении в пищу сырой рыбы. В условиях г.Алматы по статистическим данным ветеринарных клиник за последние годы (2018-2019 гг.) зарегистрировано 17 случаев диоктофимоза у собак, что составляет до 0,3% от числа исследованных по поводу гельминтозов. Появление данного, относительно нового для нашего региона заболевания, может оказать значительное влияние на эпизоотолого-эпидемиологическую обстановку. Представлены результаты прижизненной лабораторной диагностики диоктофимоза у собак овоскопическими методами, с предоставлением микрофотографий яиц паразита; методами инструментальной диагностики – ультразвуковым исследованием (УЗИ) почек с предоставлением фотографий, доказывающих наличие паразита в лоханке почки. Так как единственным методом лечения диоктофимоза является хирургическое вмешательство и извлечение диоктофим из пораженного органа (почки), приведены собственные оригинальные материалы по поэтапному оперативному вмешательству с целью извлечения гельминта из почек собак и лечения животных. Состояние прооперированных животных удовлетворительное, прогноз при проведении оперативного вмешательства благоприятный.

**Ключевые слова:** собаки, плотоядные, гельминты, гельминтозы, мониторинг, нематоды, эпизоотолого-эпидемиологическая обстановка, гематурия, диоктофимоз, УЗИ, МЭБ, ВОЗ, инвазированный материал, моча, фекалии, почки, оперативное лечение.

### Information about authors:

Balgimbayeva A., Kazakh National Agrarian University, Almaty, Kazakhstan; <https://orcid.org/0000-0002-4187-6733>

Shabdarbaeva G., Kazakh National Agrarian University, Almaty, Kazakhstan; [shgs52@mail.ru](mailto:shgs52@mail.ru); <https://orcid.org/0000-0001-5708-5162>

Zhanteliyeva Laura, Kazakh National Agrarian University, Almaty, Kazakhstan; [laura.zhanteli.@kaznau.kz](mailto:laura.zhanteli.@kaznau.kz); <https://orcid.org/0000-0002-7564-2089>

Ibazhanova A., Kazakh National Agrarian University, Almaty, Kazakhstan; [sema.serikova@mail.ru](mailto:sema.serikova@mail.ru); <https://orcid.org/0000-0002-2833-1413>

Khussainov Damir, Kazakh National Agrarian University, Almaty, Kazakhstan; [doctor-vet@mail.ru](mailto:doctor-vet@mail.ru); <https://orcid.org/0000-0002-0244-8381>

## REFERENCES

- [1] Fedorov K.P. i dr. Osnovy obshhej i prikladnoj veterinarnoj parazitologii. Novosibirsk, 2004. S. 650-655.
- [2] Akbaev M.Sh., Vasilevich F.I., Akbaev R.M., Vodjanov A.A., Kosminkov N.E., Pashkin P.I., Jatusevich A.I. – Parazitologija i invazionnye bolezni zivotnyh//M., «KolosS», 2008. S. 347-349.
- [3] Ferreira, V.L., Medeiros, F.P., July, J.R., Raso, T.F., 2010. Diocotophyme renale in a dog: clinical diagnosis and surgical treatment. Vet. Parasitol. 168, 151–155 doi:10.1016 /j.vetpar.2009.10.013
- [4] Measures, L., 2001. Diocotophymatosis. In: Samuel, W., Pybus, M., Kocan, A. (Eds.), Parasitic Diseases of Wild Mammals. Iowa State University Press/Ames, Iowa, pp. 357–364. ISBN 0-8138-2978-X
- [5] Chauhan, S., Kaval, S., Tewari, S., 2016. Diocotophymiasis: a rare case report. J. Clin. Diagn. Res. 10, DD01–DD02. doi: 10.7860 / JCDR / 2016 / 17394.7305
- [6] Sergiev V.P., Lobzin Ju.V., Kozlov S.S. Parazitarnye bolezni cheloveka (protozoozy i gel'mintozy). Rukovodstvo dlja vrachej. Sankt-Peterburg, «Foliant», 2006, S. 461-463.
- [7] Hajjalilo, E., Mobedi, I., Masoud, J., Hasanpour, H., Mowlavi, G., 2015. Diocotophyme renale in Vulpes vulpes from the Caspian Sea littoral of Iran. Iran. J. Public. Health. 44, 698–700. PMID:26284212 PMID: PMC4537628

- [8] Zolhavarieh, S.M., Norian, A., Yavari, M., 2016. Diotophyma renale (Goeze, 1782) infection in a domestic dog from Hamedan, Western Iran. Iran. J. Parasitol. 11, 131–135 Available at: <http://ijpa.tums.ac.ir>
- [9] A.S. Ibazhanova, G. S. Shabdarbyeva, N. P. Ivanov, A. M. Namet, M. A. Aliyev, D. M. Bekenov//Ketosis of cattle in the farm "Vayserke-agro» News of the national academy of sciences of the republic of Kazakhstan series of agricultural sciences ISSN 2224-526h Volume 2, Number 50 (2019), 45 – 50 <https://doi.org/10.32014/2019.2224-526H.15>
- [10] Amireev S.A. Jepidemiologija. Chastnaja jepidemiologija. 2 tom. Almaty, 2002. 687 s.
- [11] Urkhart G. i dr. Veterinarnaja parazitologija. M., «Akvarium», 2000. S. 124-125.
- [12] Zhavoronok S.V., MiCura V.M., Krasavcev E.L., Mihajlov M.I., Karpov I.A., Semenov V.M. – Tropiccheskie i parazitarnye bolezni//Minsk, «Vyshhejnaja shkola», 2014. 349 s.
- [13] Belov, A.D. Bolezni sobak /A.D. Belov, E.P. Danilov, I.I. Dikur i dr. -M.: Kolos, 1995. 2-e izd. - 205 s.
- [14] Berkinbaj O., Ahmetsadykov N. Bolezni zverej i ptic. Uchebnik. «Prints», Almaty, 2009, 432 s.
- [15] Lider L.A. Invazionnye bolezni plotojadnyh i pushnyh zverej. Tipografija KATU, Astana, 2009, 180 s.
- [16] Romanenko N.A. i dr. Sanitarnaja parazitologija. M., «Medicina», 2000. 1 Mezhdunarodnye rukovodjashhie principy tehniki bezopasnosti JuNEP v oblasti biotehnologii // JuNEP. 1995. 39 s.
- [17] Informacionnyj bjulleten' № 99 Vsemirnoj organizacii zdravoohraneniya. Ijul' 2013 g. [Jelektronnyj resurs]. – Rezhim dostupa: <http://www.who.int/mediacentre/factsheets/fs099/ru/>
- [18] Kereev Ja.M. Jehinokokkoz zhivotnyh. Monografija -Ural'sk, 2010.- 197 s.
- [19] Shalmenov M.Sh. Rekomendacii po profilaktike jehinokokkoza s/h zhivotnyh v Zapadno-Kazahstanskoj oblasti. – Ural'sk, 2005. – 18 s.
- [20] Akshulakov S.K. Jehinokokkoz cheloveka //Almaty, 2002. – 86 s.
- [21] Shabdarbaeva G.S., Abdibekova A.M., Shapieva Zh.Zh. Antropozoonozy i mery ih profilaktiki v Respublike Kazahstan//Monografija. Almaty, «S-Print», 2012, 104 s.
- [22] Shabdarbaeva G.S., Abdybekova A.M., Shalmenov M.Sh., Shapieva Zh.Zh. - Jepizootologo-jepidemiologicheskij analiz zoonoznyh gel'mintozov v zapadnyh regionah Kazahstana//Materialy Mezhdunarodnoj nauchno-prakticheskoy konferencii «Veterinarija v HHI veke: problemy, metody, reshenija», KazATU, g.Astana. 2016. S. 216-220.
- [23] «Rekomendacii po kontrolju zoonoznyh gel'mintozov v Kazahstane»//Rekomendacii. Almaty, Izd-vo «Print-Master», 2017. 50 s. (Avtory: G.S.Shabdarbaeva; D.M.Husainov, S.S.Amirgalieva, H.B.Abeuov; G.E.Turganbaeva, A.S.Ibazhanova, Zh.Zh.Kenzhebekova; A.I.Balgimbaeva.
- [24] Mandrykina Ul'jana, Shabdarbaeva G.S. - Sluchaj dioktofimoza u sobaki v g.Almaty//Materialy X Mezhdunarodnoj studencheskoj jelektronnoj nauchnoj konferencii «Studencheskij nauchnyj forum-2018», Moskva, 2018. Sajt: <http://scienceforum.ru/2018/3/7953>.
- [25] Metodicheskie rekomendacii «Metody issledovanija ryb»//Metodicheskie rekomendacii utverzhdeny na NTS NII problem animalogii pri KazNAU. Izd-vo «PRINT-MASTER», Almaty, 2017. 35 s. = 1,5 p.l. (Shabdarbaeva G.S., Isbekov K.B., Asylbekova S.Zh., Kojshybaeva K.K., Ibazhanova A.S., Kenzhebekova Zh.Zh., Turganbaeva G.E.).
- [26] «Rekomendacii po patologicheskoy morfologii parazitarnyh boleznej ryb»//Rekomendacii utverzhdeny na NTS NII problem animalogii pri KazNAU. Izd-vo «PRINT-MASTER», Almaty, 2017. 20 s. = 1,5 p.l. (Shabdarbaeva G.S., Isbekov K.B., Asylbekova S.Zh., Kojshybaeva K.K., Ibazhanova A.S., Kenzhebekova Zh.Zh., Turganbaeva G.E.).
- [27] Shabdarbaeva G., Ibazhanova A., Kenzhebekova Zh., Balgimbayeva A., Zhanteliyeva L. - Clinical-morphology of moneyosiosis in sheep // zhurnal «Izvestija NAN. Serija agrarnyh nauk», №3(45) 2018. ISSN 2224-526X. Maj-ijun'. P. 67-72.

## **Publication Ethics and Publication Malpractice in the journals of the National Academy of Sciences of the Republic of Kazakhstan**

For information on Ethics in publishing and Ethical guidelines for journal publication see <http://www.elsevier.com/publishingethics> and <http://www.elsevier.com/journal-authors/ethics>.

Submission of an article to the National Academy of Sciences of the Republic of Kazakhstan implies that the described work has not been published previously (except in the form of an abstract or as part of a published lecture or academic thesis or as an electronic preprint, see <http://www.elsevier.com/postingpolicy>), that it is not under consideration for publication elsewhere, that its publication is approved by all authors and tacitly or explicitly by the responsible authorities where the work was carried out, and that, if accepted, it will not be published elsewhere in the same form, in English or in any other language, including electronically without the written consent of the copyright-holder. In particular, translations into English of papers already published in another language are not accepted.

No other forms of scientific misconduct are allowed, such as plagiarism, falsification, fraudulent data, incorrect interpretation of other works, incorrect citations, etc. The National Academy of Sciences of the Republic of Kazakhstan follows the Code of Conduct of the Committee on Publication Ethics (COPE), and follows the COPE Flowcharts for Resolving Cases of Suspected Misconduct ([http://publicationethics.org/files/u2/New\\_Code.pdf](http://publicationethics.org/files/u2/New_Code.pdf)). To verify originality, your article may be checked by the Cross Check originality detection service <http://www.elsevier.com/editors/plagdetect>.

The authors are obliged to participate in peer review process and be ready to provide corrections, clarifications, retractions and apologies when needed. All authors of a paper should have significantly contributed to the research.

The reviewers should provide objective judgments and should point out relevant published works which are not yet cited. Reviewed articles should be treated confidentially. The reviewers will be chosen in such a way that there is no conflict of interests with respect to the research, the authors and/or the research funders.

The editors have complete responsibility and authority to reject or accept a paper, and they will only accept a paper when reasonably certain. They will preserve anonymity of reviewers and promote publication of corrections, clarifications, retractions and apologies when needed. The acceptance of a paper automatically implies the copyright transfer to the National Academy of Sciences of the Republic of Kazakhstan.

The Editorial Board of the National Academy of Sciences of the Republic of Kazakhstan will monitor and safeguard publishing ethics.

Правила оформления статьи для публикации в журнале смотреть на сайте:

[www.nauka-nanrk.kz](http://www.nauka-nanrk.kz)

<http://agricultural.kz/index.php/en/>

Редактор *М. С. Ахметова, Т. М. Апендиев, Д. С. Аленов*  
Верстка на компьютере *Д. Н. Калкабековой*

Подписано в печать 06.12.2019.

Формат 60x881/8. Бумага офсетная. Печать – ризограф.  
4,9 п.л. Тираж 300. Заказ 6.